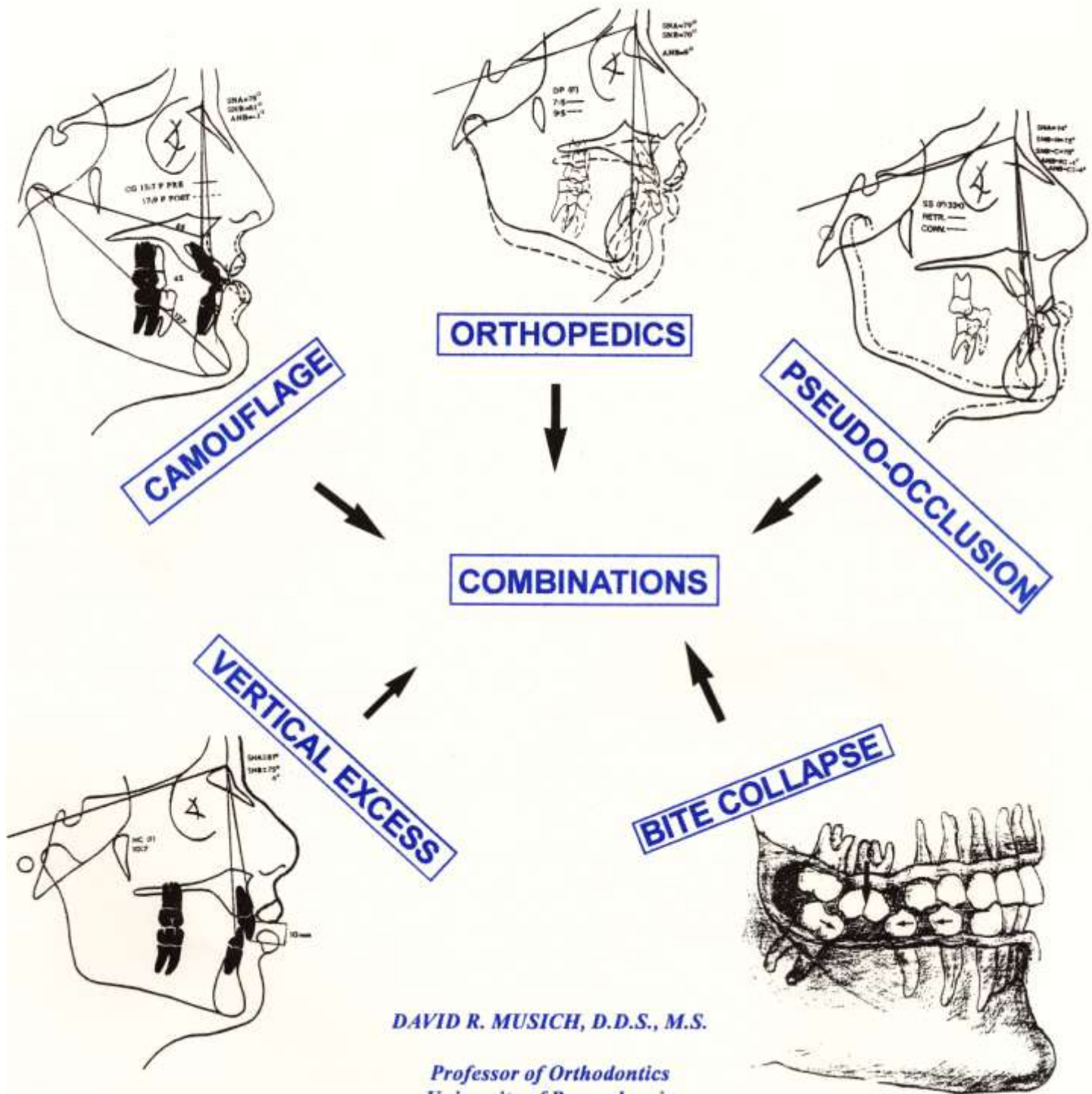


NON-SURGICAL TREATMENT OF  
SKELETAL MALOCCLUSIONS  
COMPROMISE CASE?  
OR  
CONSERVATIVE CARE?



DAVID R. MUSICH, D.D.S., M.S.

Professor of Orthodontics  
University of Pennsylvania  
School of Dental Medicine

# Non-surgical management of skeletal malocclusions: An assessment of 100 cases

In early 1970's reduced risks associated with surgical procedures allowed the treatment planning process for skeletal malocclusions to become **problem oriented**. During the 1980's and early 1990's moderate and severe skeletal imbalances were routinely treatment planned and treated with orthodontics and orthognathic surgery. In the last eight years insurance coverage have limited patient's access to orthognathic treatment, therefore the orthodontist must undertake a more sophisticated process of differential diagnosis and treatment planning. As a result of the barriers placed by insurance companies, patients are asking orthodontists—"What are my options? What are the risks? Do the benefits outweigh the risks? Will there be a benefit if I choose not to have the orthognathic procedure that is indicated and just have orthodontics?"

**This paper evaluated 100 patients who were treatment planned *with an initial plan of orthodontics and orthognathic surgery*, but who, for a variety of reasons, were ultimately treated without orthognathic surgery. Six skeletal case types** that appear to be surgical problems but responded favorably to non-surgical management will be described both cephalometrically and behaviorally. Treatment modalities will be presented along with examples of treatment results for all **six groups**.

When undertaking the treatment of skeletal problems with a non-surgical approach, orthodontists must pay special attention to the following **patient management** considerations:

- Patient education to clarify options
- Clarification of treatment goals and prioritization of the goals with the patient and the general dentist (*ideal outcomes are not usually achievable without jaw surgery for skeletal cases*)
- Medicolegal and ethical factors that play a key role as orthodontists counsel patients to consider high risk treatment plans (surgery) in accordance with the diagnosis or low risk plans (orthodontics only) that may not only camouflage the skeletal problem
- Methods of assessing treatment orthopedic treatment response through the measurement of growth vectors
- Summarization and review of treatment outcome with the patient and the dentist

Orthodontists have many mechanisms to correct malocclusions. This report will encourage orthodontist specialists to **value therapeutic diagnosis** in the management of certain types of skeletal malocclusions and will demonstrate that assessing **treatment response** is an important component of the dynamics of the diagnostic and treatment process. Important **patient management** steps listed above will be emphasized. This report demonstrates that certain types of skeletal malocclusions that appear to require jaw surgery have the potential to be well treated with conventional, non-surgical orthodontic measures.

**NON-SURGICAL MANAGEMENT OF SKELETAL MALOCCLUSIONS :**  
**Compromise case or Conservative care?**  
***The Orthodontists \$20 Billion Decision***

**I. Introduction**

- Advantages of orthognathic surgical treatment
- Risks of orthognathic surgical treatment

**II. **What is a *Borderline Surgical Case*?****

- Treatment Goals
- Treatment Planning Options

**III. Case Types Frequently Treatment Planned for Surgery When Other Options are Available**

- What case types are in this "borderline" category?
- What are the cephalometric criteria:?
- What diagnostic and treatment planning tools are useful?
- Can examples of these concepts be demonstrated?

**IV. How can orthodontists routinely provide quality care and reduce surgical intervention?**

---

---

---

---

---

---

---

---

# **NON-SURGICAL OPTIONS FOR PATIENTS WITH SKELETAL MALOCCLUSIONS COMPROMISE CASE OR CONSERVATIVE CARE?**

## *Consideration in the Non-Surgical Management of Skeletal Imbalances*

### **INTRODUCTION:**

A brief history

Who needs orthognathic surgery?

Are all treatment goals created equal?

Where does patient satisfaction fit in?

Awareness of options!

Medico-legal issues!

Concept of over-treatment under-treatment!

Where are the problems?

### **NON-SURGICAL MANAGEMENT OF SKELETAL IMBALANCES:**

#### **I. CAMOUFLAGE THERAPY**

Do you occasionally underestimate the effectiveness of camouflage therapy?

#### **II. ORTHOPEDIC THERAPY**

Have you ever underestimated the effectiveness of available methods of growth modification?

#### **III. ALVEOLAR COLLAPSE**

Do you occasionally misdiagnose the impact of arch collapse?

#### **IV. PSEUDO-OCCLUSION (CO / CR DISCREPANCY)**

Have you ever misdiagnosed the amount of functional shift?

#### **V. VERTICAL MAXILLARY EXCESS**

Do you sometimes misdiagnose the degree of skeletal vertical excess?

#### **VI. COMBINATIONS**

Do you ever consider how combinations of the above problems can look like true surgical cases, but may possibly be treated non-surgically?

# I. CAMOUFLAGE THERAPY

Underestimation of effectiveness

## A. History and Semantics

1. "Acceptable Compromise" - Limits?
2. Dental Compensation: - Limits?
3. Camouflage

## B. Four General Types

1. Camouflage thru differential extraction
2. Camouflage thru non-extraction and incisor re-angulation
3. Camouflage and stabilize thru addition of teeth
4. Camouflage through incisor re-angulation and genioplasty
5. Re-angle incisors; accept partial correction of overjet; improve function  
(a.k.a--*Independent alignment*)

## C. Craniofacial Characteristics

1. Moderate basal bone discrepancy - both jaws contribute;  
50% maxillary protrusion / 50% mandibular deficiency
2. Adequate alveolar bone and gingivae for incisor re-angulation
3. Contra-indicated in severe, one jaw imbalances;  
100% mandibular deficiency

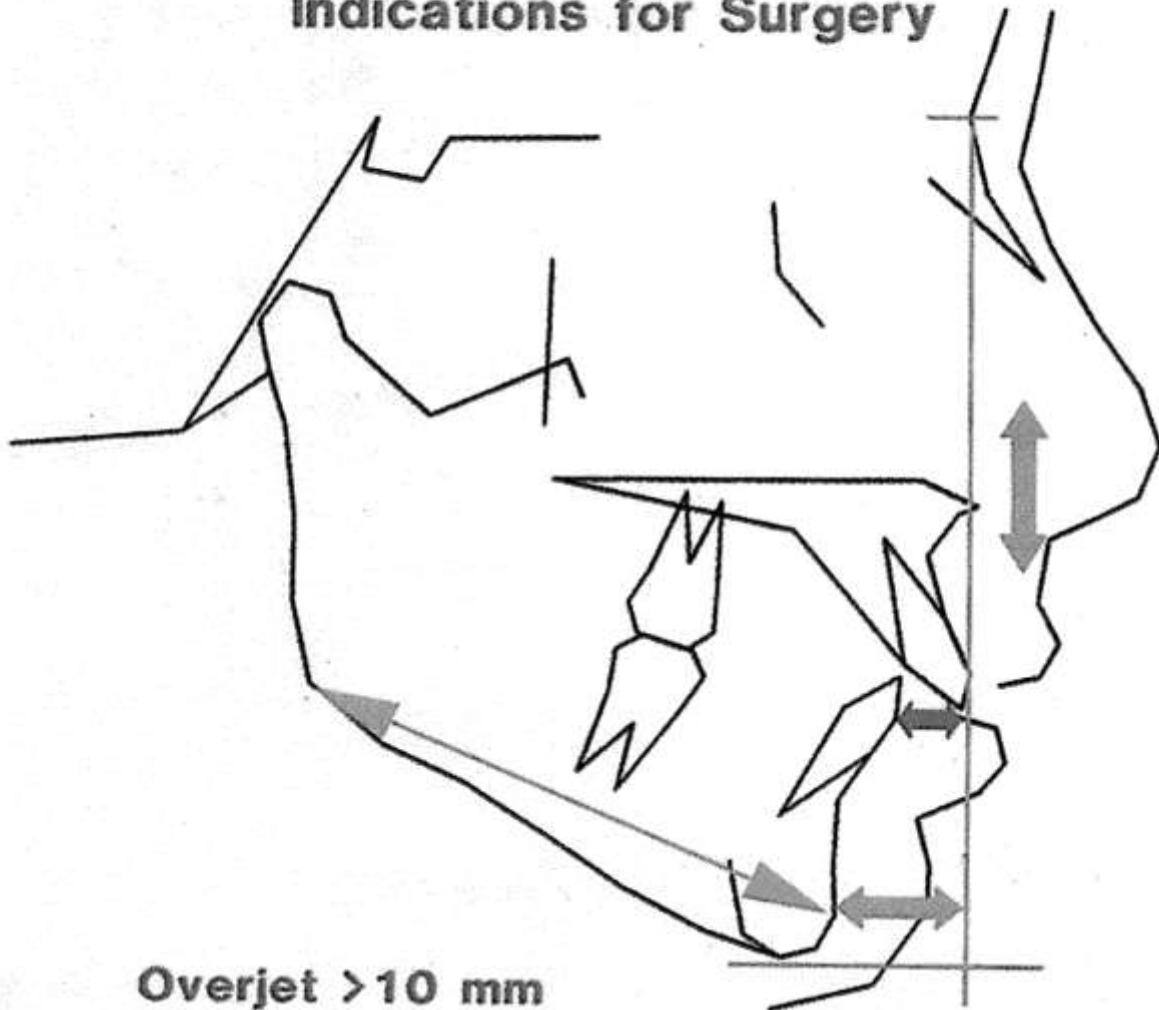
## D. Behavioral Characteristics of Patient

1. Existing facial proportion acceptable to patient
2. Proposed angular changes of teeth acceptable

## E. Key points

- Clear diagnosis of degree of skeletal problem  
(*Bolton Template assistance for both doctor and patient understanding*)
- Explain options: "ideal versus practical"  
(*What are the downsides of practical plan—short term & long-term--your view?*)
- Avoid over-retraction of upper incisors  
(*Frequently requires non-x lower, with en. re-contouring and gingival grafting to accomplish non-x goal on lower arch*)
- In treatment plan write-up (*the paper trail*)—indicate both plans and why practical was chosen (*risk/benefit issues; pt. concern issues*)
- Understand how camouflage treatment affects facial aging—long term factors

## ADOLESCENT CLASS II Indications for Surgery



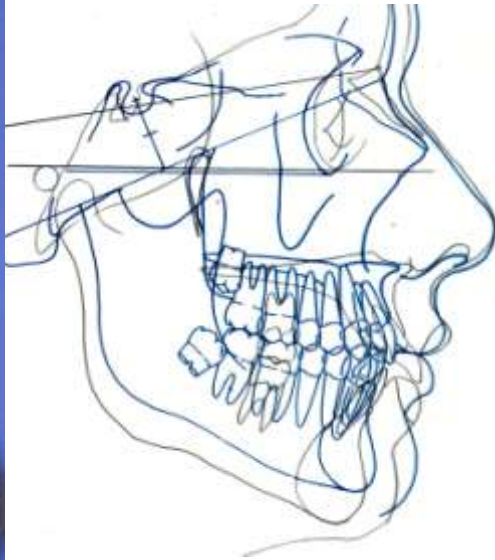
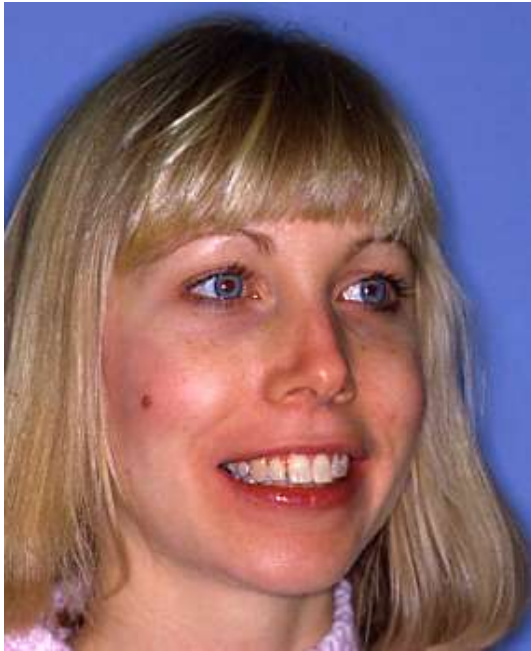**Overjet >10 mm**

especially if

- (1) Pg-NPerp >18 mm
- (2) Mand body length <70 mm
- (3.) Face height >125 mm

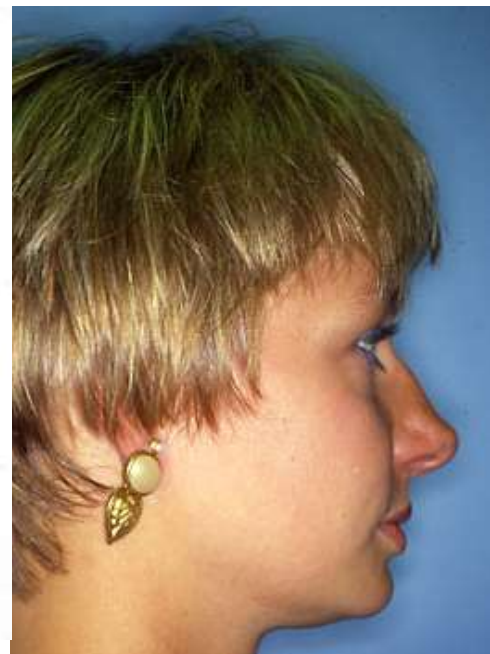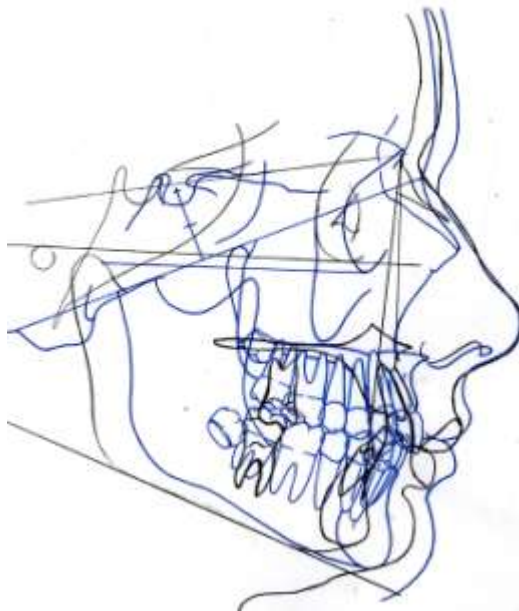
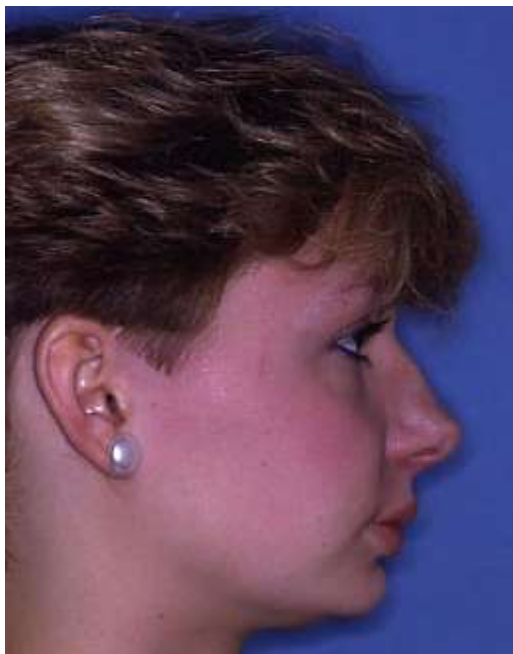**Proffit, William R., Phillips, Ceib, Tulloch, J.F. Camilla, and Medland, Patricia H.** *Surgical versus orthodontic correction of skeletal Class II Malocclusion in adolescents: Effects and indications;* The Int J of Adult Orthod and Orthognath Surg. Vol.7:4; 1992; 209-220.

## Indications for Class II camouflage treatment—*classic case*



## Contraindications for Class II camouflage treatment—*good example*

From Garber, Vanarsdall, Vig: Current Concepts and Techniques in Orthodontics IV Edition, 2006



## **II. ORTHOPEDIC THERAPY**

Underestimation of effectiveness

### **A. Historical Perspective**

1979 - Wolford, Schendel, Epker

1991 - Snow, Turvey, Walker, Proffit

1985 - Vagervike, Harvold

#### **Wolford's Study**

12 growing children (8 - 16)

Follow-up - 2 years to 5 years 7 months

Average advancement 5.4 mm

#### **Conclusion:**

"Mandibular advancements can be safely and successfully performed in actively growing patients with expected harmonious growth between maxilla and mandible."

#### **Snow and Turvey's Study**

12 adolescents (12 to 15)

Follow-up - 1 year to 7 years

Average advancement 6.25mm

#### **Conclusion:**

"Forward growth of maxilla is minimal after the peak of adolescent growth spurt, and results of mandibular advancement can be acceptably stable after that time."

#### **Vargevick and Harvold's Study**

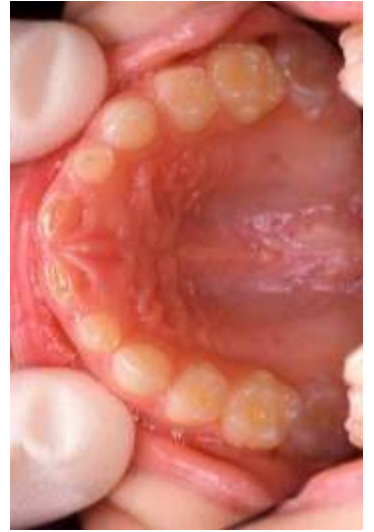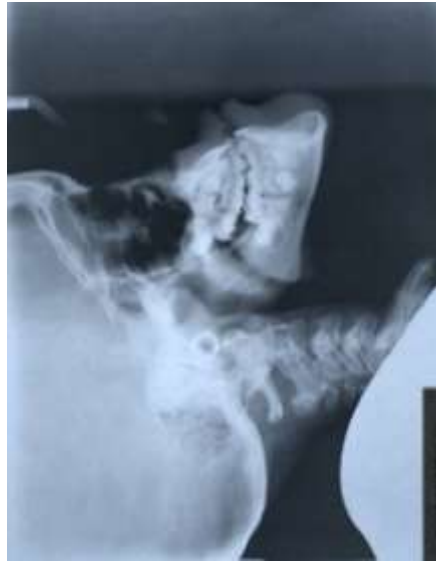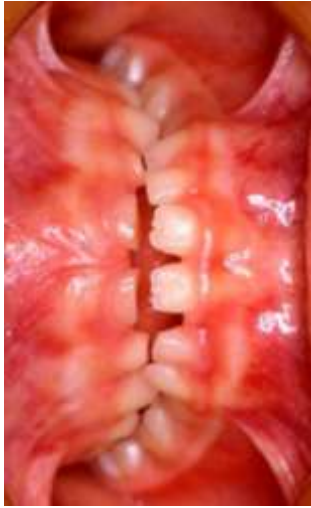#### **Conclusion:**

Class II malocclusions in growing patients can be treated with an activator and the following results can be expected:

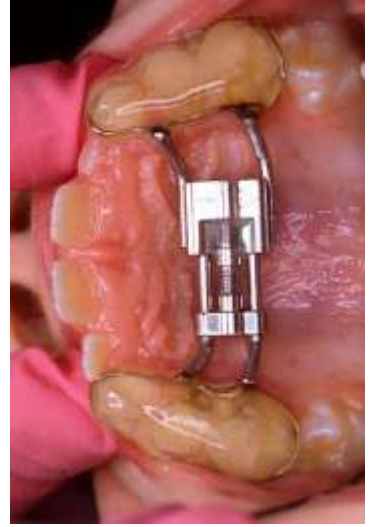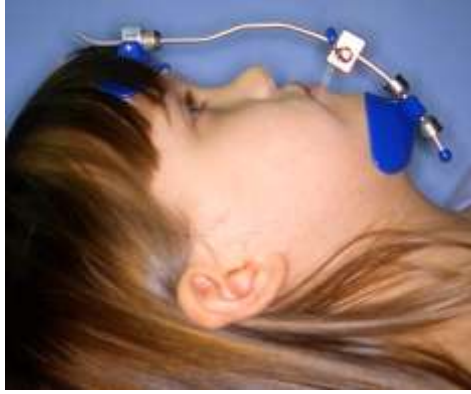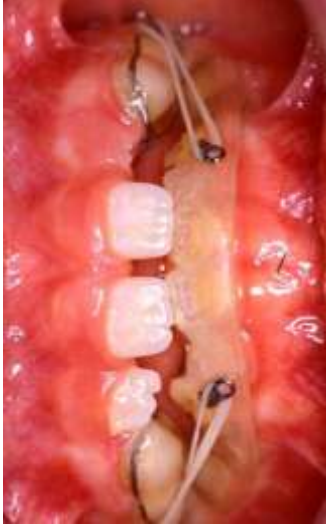1. Correction of Class II molar
2. Correction of overjet
3. Leveling of the occlusal plane
4. Increased advancement of all mandibular structures

# Reverse Pull Headgear

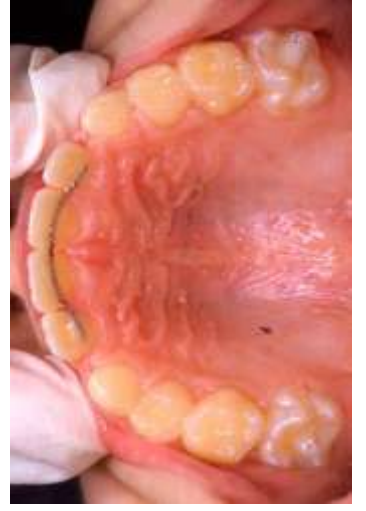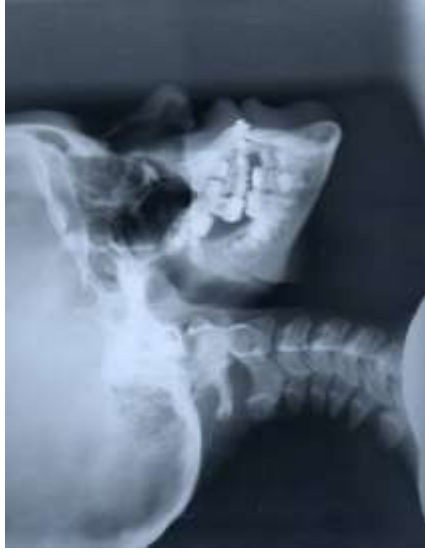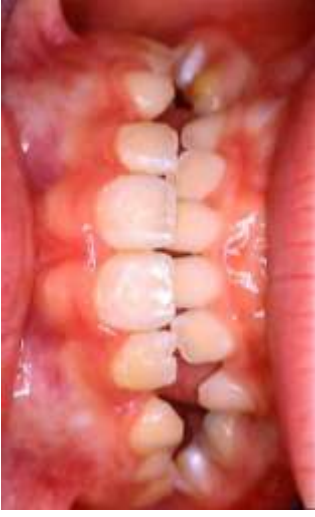Pre-Treatment



During Treatment with Traction

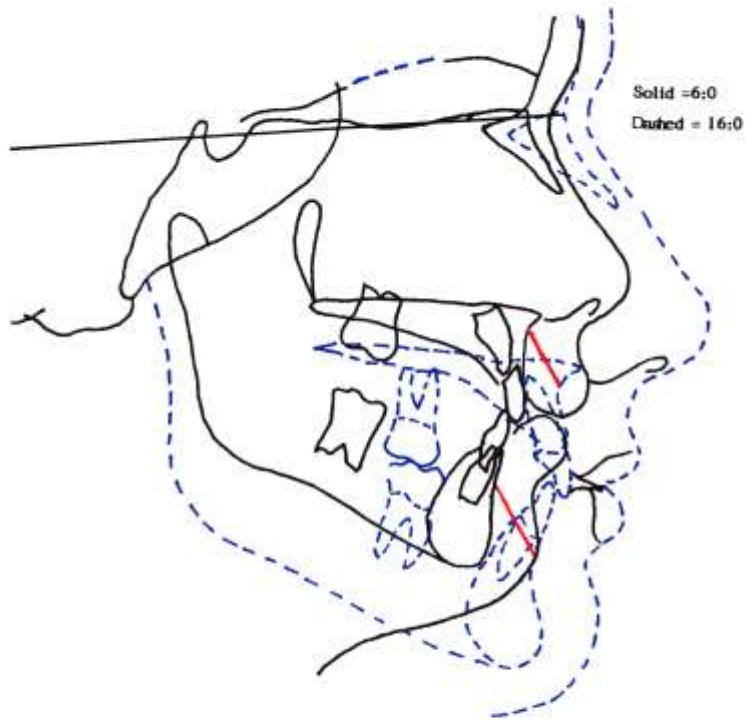


After Phase I Treatment



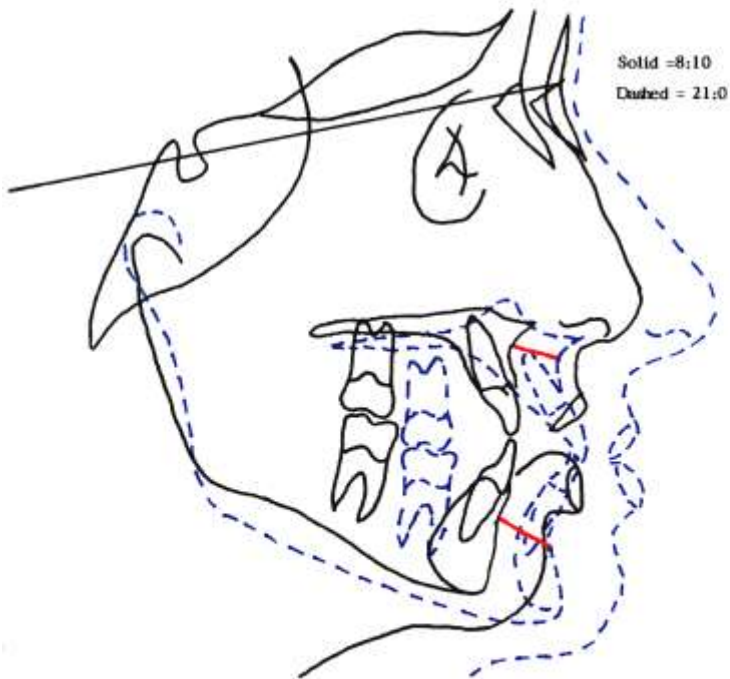
# Bolton Standard Ages 6-16

Superimposition on SN



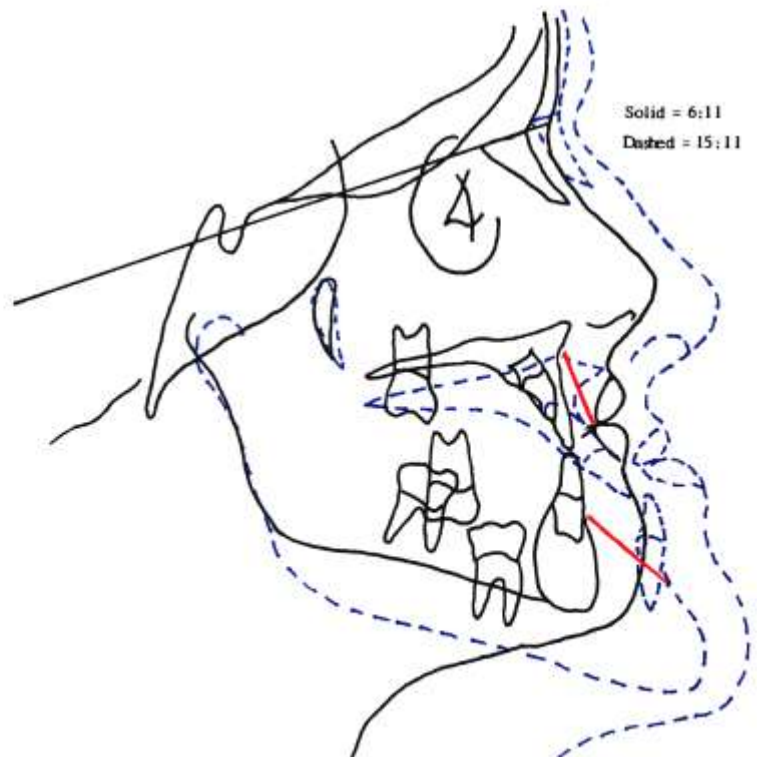
## Non-Surgical Class III (K.G. 8:10--21:0)

Superimposition on SN



## Surgical Class III (E.F. 6:11--15:11)

Superimposition on SN

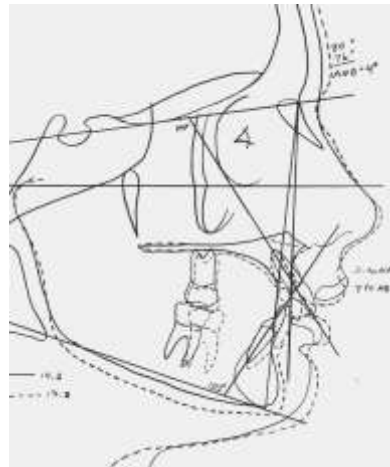
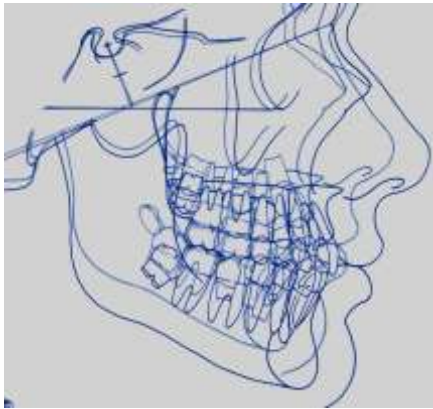


## II. ORTHOPEDIC THERAPY (Continued)

Underestimation of effectiveness

### B. Case Characteristics (Class II or Class III)

1. Moderate A - P discrepancy (both jaws contributing to skeletal imbalance)
2. Favorable familial pattern
3. Excellent compliance
4. Early positive growth response (serial cephs)

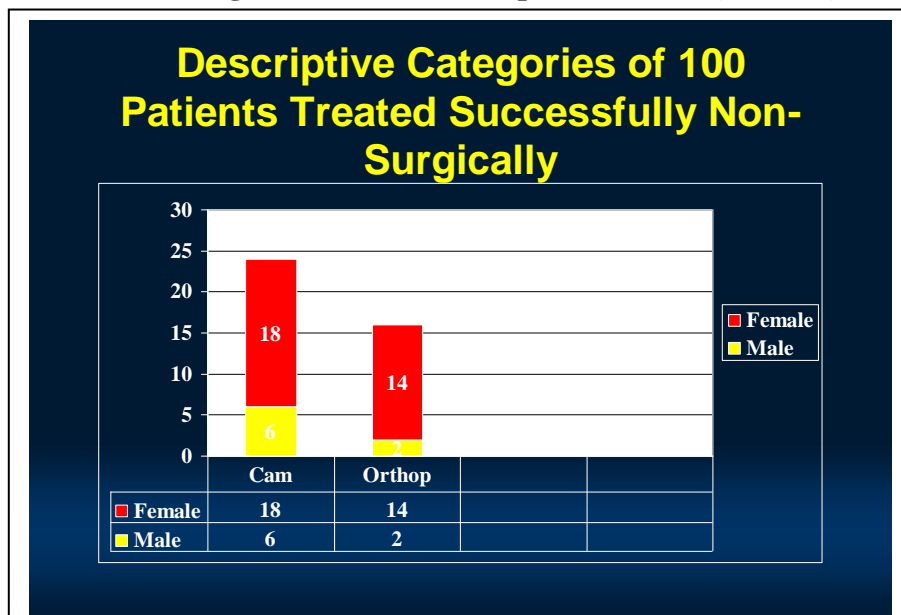


### C. Contra-Indications

1. Family history of mandibular excess; cephalometric analysis of parents helps
2. Family history of severe mandibular deficiency with clockwise growth pattern; cephalometric analysis of parents helps to provide baseline.

### D. Author's Note

**Therapeutic modifiability** is an individual case characteristic with several variables which require application of orthopedic principles and re-assessment of **growth treatment response vectors (GTRV)**.



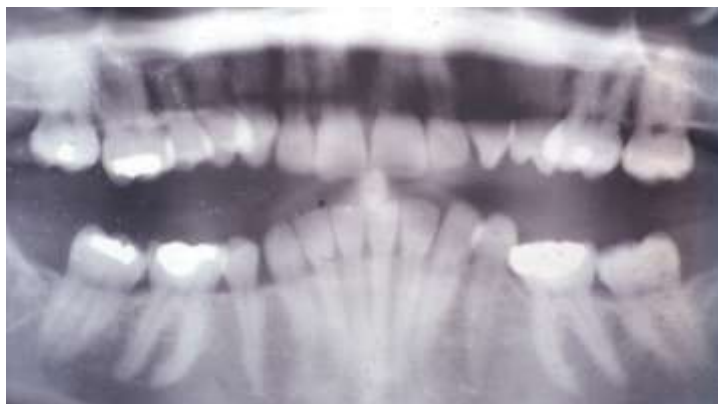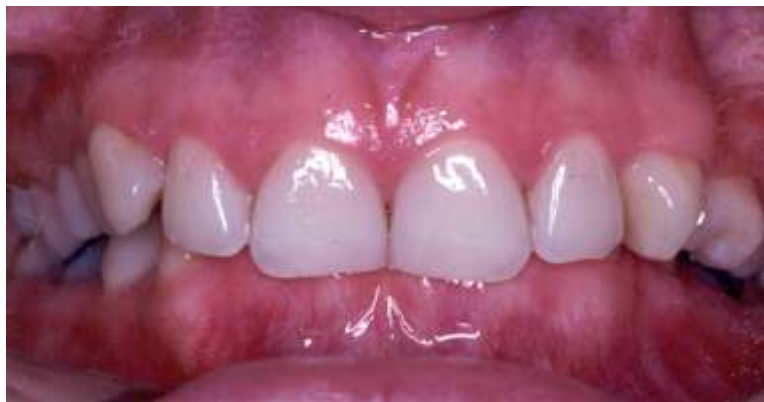### III. ALVEOLAR COLLAPSE

Misdiagnosis of impact

#### A. Historical Perspective

#### B. Case Characteristics (Class II or Class III)

1. Moderate skeletal disharmony - both jaws contribute
2. Tooth loss thru extraction or congenital absence results in alveolar atrophy
3. Alveolar hypertrophy occurs in the opposing arch due to lack of vertical stops
3. Passage of time exacerbates the appearance of a true skeletal imbalance



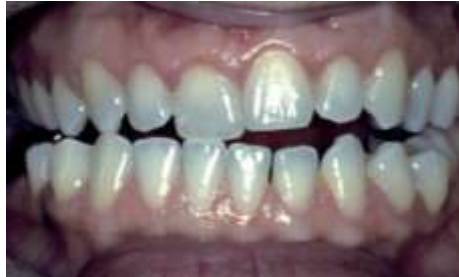#### C. Author's Note

Decompensation and tooth replacement are more conservative and more predictable than space closure and orthognathics. Be aware that alveolar collapse can both mimic or be a component of true skeletal disharmony.

#### IV. PSEUDO-OCCLUSION (CO / CR DISCREPANCY)

Misdiagnosis of amount

##### A. Historical Perspective

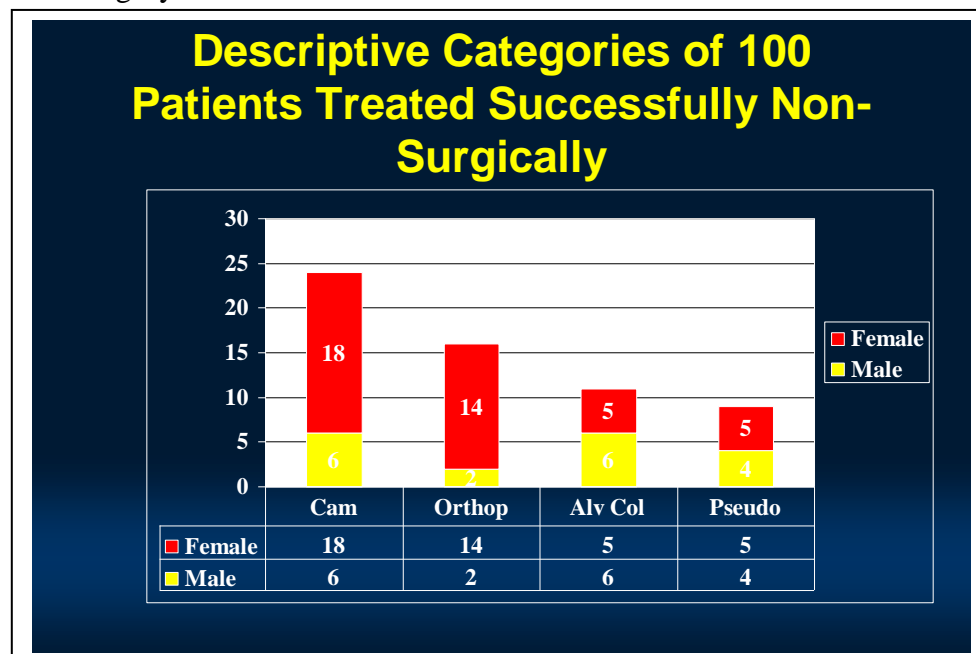


##### B. Case Characteristics (Class II or Class III)

1. Moderate basal bone discrepancy - both jaws contribute
2. 1 to 3 mm functional shift of mandible
3. Degree of mandibular excess and future growth
4. Adequate labial plate of maxilla / mandible
5. Considerations of incisor stability
6. Long-term TMJ stability with new position needs assessment
7. Periodic re-evaluation necessary

##### C. Author's Note

Future growth, TMJ response, and labial plate adaptation are all variables that need constant monitoring in the management of this category.



## V. VERTICAL MAXILLARY EXCESS

Misdiagnosis of amount

### A. Historical Perspective

### B. Case Characteristics (Class I, II, III)

1. Moderate degree of gingival excess with hyperplastic tissue
2. Chief complaints:  
crooked teeth  
"too much gum with smile"
3. Minimal lip incompetence
4. Lower face height and chin acceptable

### C. Treatment Plan

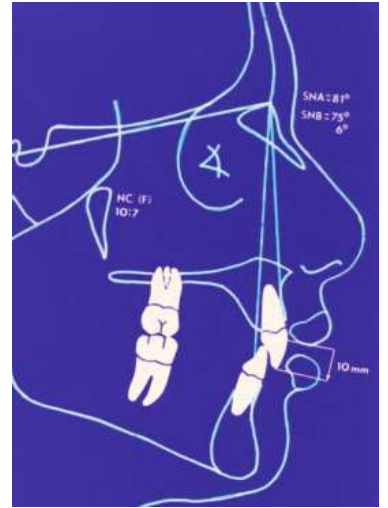
1. Conventional Orthodontics
2. Hi pull headgear
3. Gingivoplasty

### D. Contra-Indications

True vertical maxillary excess with lip incompetence and facial imbalance (ie long face syndrome)

### E. Author's Note

Good Headgear cooperation and acceptance of gingivoplasty procedure can provide exceptional results without LeFort osteotomy and the inherent risks. Differential diagnosis is critical.



## **VI. COMBINATIONS OF PRECEDING FIVE CATEGORIES**

### **Combo Case #1 - Alveolar Collapse and Vertical Maxillary Excess**

Diagnosis:

- Class I molars
- Class II anterior with anterior bite collapse
- Gingival excess
- Missing #23 (lower left incisor)

Treatment Plan:

- Reverse bite collapse
- Intrude upper and lower incisors
- Stabilize - replace incisor
- Gingivoplasty

### **Combo Case #2 - Alveolar Collapse / Camouflage / Gingival Excess**

Diagnosis:

- Class III with asymmetry
- Alveolar collapse
- Spacing
- Gingival excess

Treatment Plan:

- Reverse Collapse
- Camouflage thru advancement of upper incisors; retract lower incisors
- Reduce gingival excess
- Accept prominent mandible
- Accept moderate asymmetry

### **Combo Case #3 - Orthopedics / Alveolar Collapse / Camouflage**

Diagnosis:

- Class III
- Alveolar collapse

Treatment Plan:

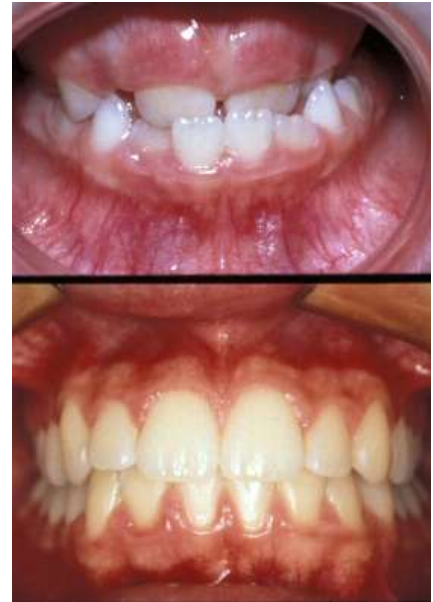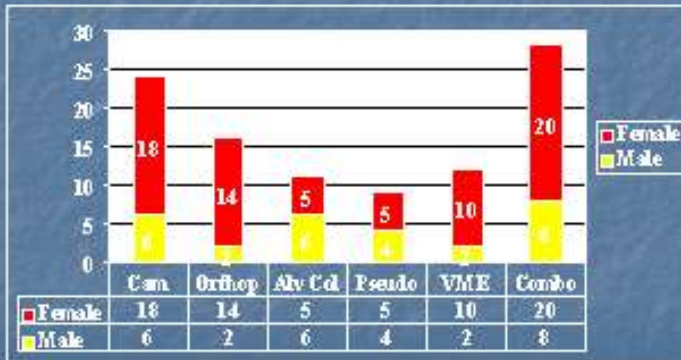
- Palatal expansion
- Class III traction - staged
- Replace missing incisors prosthetically

### **Combo Case #4 - Orthopedics / Alveolar Collapse / Camouflage**

Treatment Plan:

- Palate expansion
- Class III traction - staged
- Dental camouflage as needed for anterior function

## Descriptive Categories of 100 Patients Treated Successfully Non-Surgically



### **SUMMARY:**

- This study evaluated 100 patients who had a primary treatment plan of jaw surgery to correct a skeletal disharmony.
- Retrospective assessment found that all 100 patients were treated with non-orthognathic treatment measures. A high degree of patient satisfaction occurred with treatment.
- Orthodontists are the only dental professionals that have the training to diagnose and treat skeletal malocclusions.
- A 6<sup>th</sup> category that combines several of the first 5 categories, provides the most powerful & effective approach to solving borderline skeletal problems nonsurgically.
- With simple math interpolation, it appears that orthodontists are reducing health care costs by 20 billion dollars/year.