

Early Class III Treatment:

What are the Non-surgical limits?

American Association of Orthodontists

Annual Session

Chicago—May 15, 2011

Presented by: David R. Musich, DDS, MS

Clinical Professor of Orthodontics

University of Pennsylvania, School of Dental Medicine

Department of Orthodontics

Email: drmusich@aol.com

Web address: www.MusichBuschOrtho.com

Early Class III Treatment

What are the non-surgical limits?

How is the decision made?

When can we find out?

I. Goals for early treatment Class III patients

F unction

R2 eliable/**R**ealistic

E2 sthetics/**E**conomic

S2 tability/**S**atisfaction

H ealth

II. Differential diagnosis of growing Class III pts

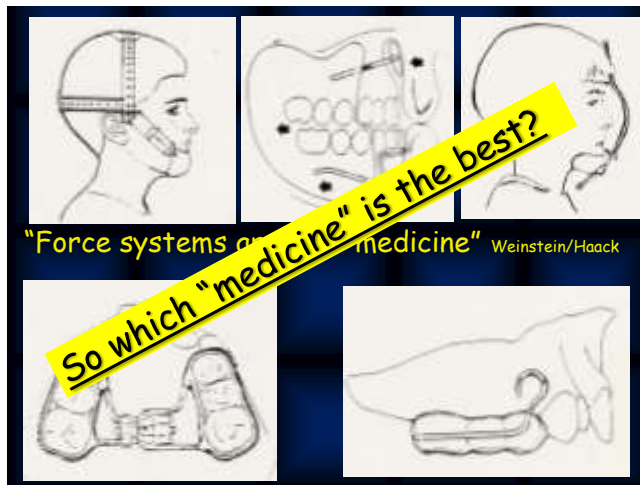
McNamara, Guyer, et al: A.O., 1986
Components of Class III Malocclusion
5-15 year old studied; Ceph assessment

1.	Mnd. skeletal prognathism	20%
2.	Max. skeletal retrusion	25%
3.	Max. skel. Retru. & Mnd. Progn.	22%
4.	Normal Max./Mnd. (Ant. Crossbite)	33%

Differential diagnosis:

- Diagnostic deficiency in the Angle system
- Helpful diagnostic nomenclature change:
 - *Class III* descriptor for growing patients changes to *Class III-ing* i.e., an action verb rather than a static noun.
 -
 - Changes *static diagnosis*, to *dynamic diagnosis*.
- Also term, *Pseudo-Class III*, confuses diagnostic process—preference, *Class III* skeletal pattern exacerbated by functional shift of mandible

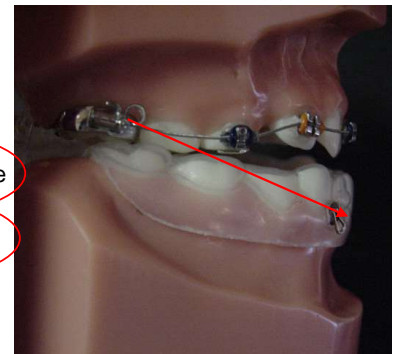
III. Effective therapeutic measures



ORTA®

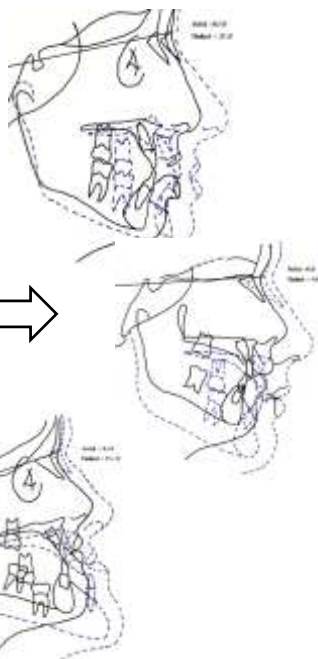
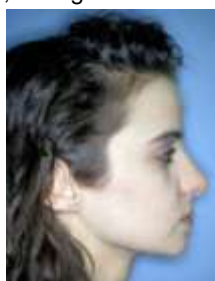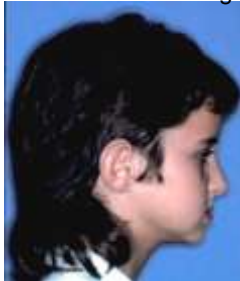Orthodontic Removable Traction Appliance

- ✓ Intraoral
- ✓ Inexpensive
- ✓ High compliance
- ✓ Disarticulation
- ✓ Easily adjusted

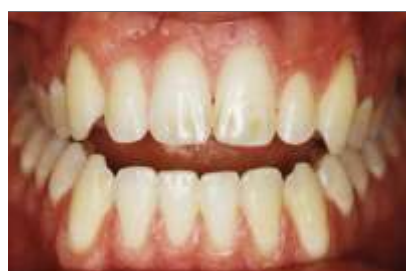
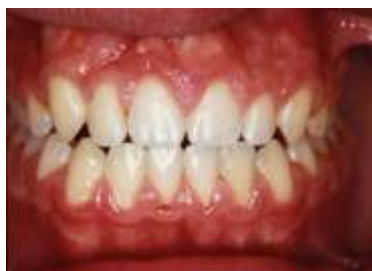
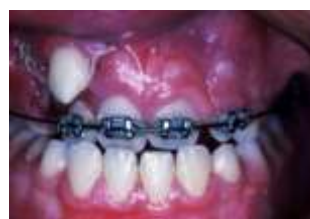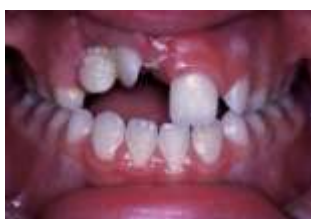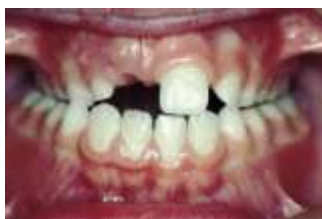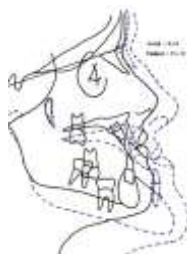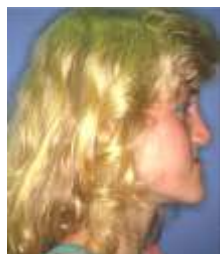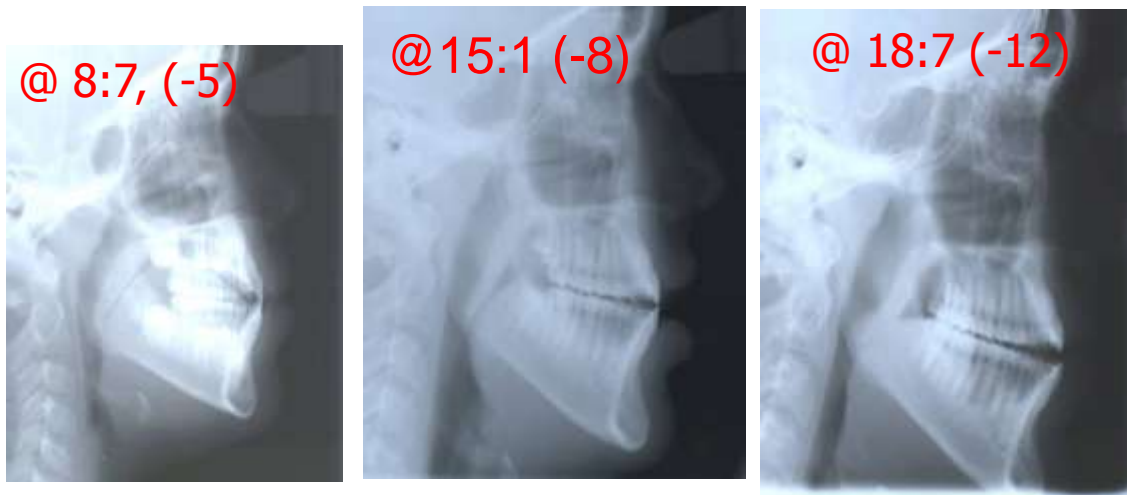
IV. Treatment response—assessment (Changes in Wits measurement, preferred)

Class III—Treated non-surgically; note growth vectors of A1-A2 & B1 to B2



Bolton Standard—Normal Growth 6-16 Σ \Rightarrow





V. ***Additional variables to review at Phase II conference***

Additional variables that need consideration:

(Seldom discussed but can be critical)

- Psychological factors of appearance
- Transverse deficiency of maxilla (*skeletal component*); space available (*dental component*)
- Clockwise growth & excessive mand. growth
- Asymmetrical growth
- True condylar hyperplasia
- Short stature/Class III: Rx human growth hormone

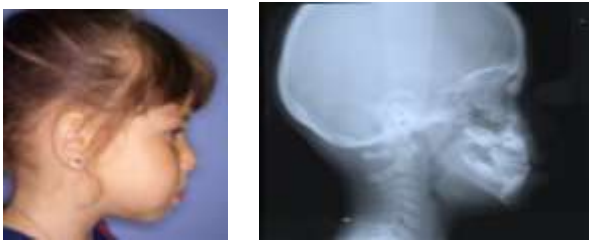VI. Application of treatment principles—checklist & case reports

Checklist (at Phase II) for Class III-ing Pts.

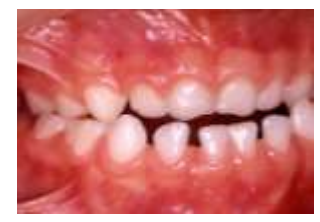Patient's Name: _____		Age _____	Skel. Age _____
Male	<u>Female</u>		
✓ Family history	Yes	No	_____
✓ Initial diagnosis (mnd excess)	Yes	No (%Max vs. Mand)	_____
✓ Response to Ph I	Good	Fair	Poor _____
✓ Diagnosis @ Ph II (Wits)	Better	Same	Worse
✓ Facial balance	Mild	Mod.	Severe
✓ Skeletal age @ Ph II	Favorable	Unfavorable	_____
✓ Growth pattern	Favorable	Unfavorable (asym/open)	_____
✓ Ging Health/Root length	Favorable	Unfavorable	_____
✓ Capacity to Camouflage	Favorable	Unfavorable	_____
✓ Compliance	Favorable	Unfavorable	_____
✓ Growth hormone	Yes	No	
Phase II Decision Time: Non-surg; Thera dx; Wait & plan surg.			

Case #1

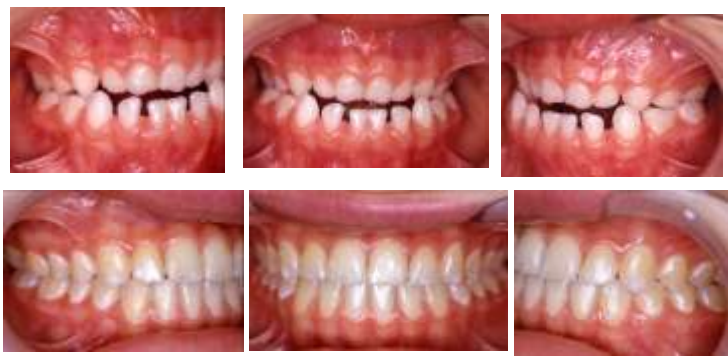Case I
(Age 5-6)



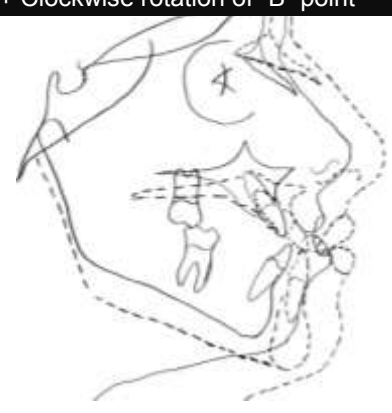
ANB = +3.5°
Mx/Mnd = 20mm
WITS = -5mm



A.C.—Before and after

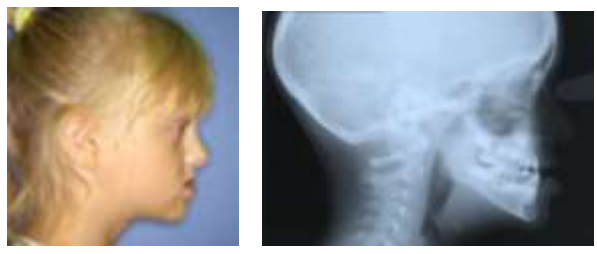

Orthopedics + Camouflage + Fx Shift Elim.
+ Clockwise rotation of "B" point ***

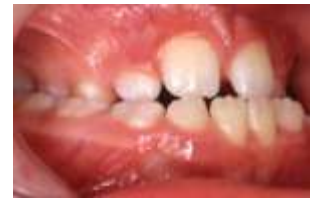

Case # 2

Case II
(Age 9)



ANB = -0.5°
Mx/Mnd = 27mm
WITS = -7mm



Checklist (at Phase II Conf.) for Class III-ing Pts.

Hypothesis

All early Class III's require Therapeutic Dx

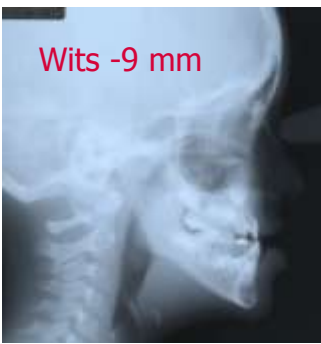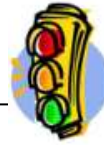Patient's Name: Erin A. Age _____ Skel. Age _____

Male

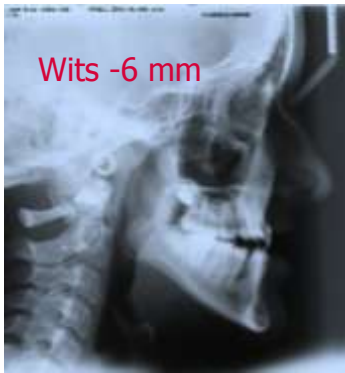Female

- | | | |
|----------------------------------|------------------|--------------------------------|
| ✓ Family history | Yes | No _____ |
| ✓ Initial diagnosis (mnd excess) | Yes | No (%Max vs. Mand) _____ |
| ✓ Response to Ph I | Good | Fair Poor _____ |
| ✓ Diagnosis @ Ph II (Wits) | Better | Same Worsening |
| ✓ Facial balance | Mild | Mod. Severe |
| ✓ Skeletal age @ Ph II | Favorable | Unfavorable _____ |
| ✓ Growth pattern | Favorable | Unfavorable (asym/open) |
| ✓ Ging Health/Root length | Favorable | Unfavorable _____ |
| ✓ Capacity to Camouflage | Favorable | Unfavorable _____ |

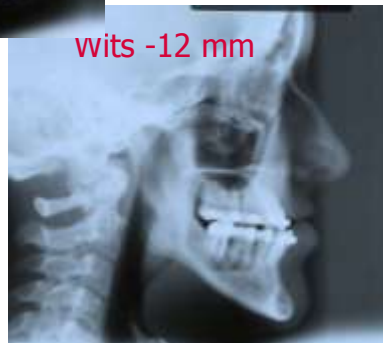Phase II **Decision Time:** Non-surg; Thera dx; **Wait & plan surg.**



Wits -9 mm

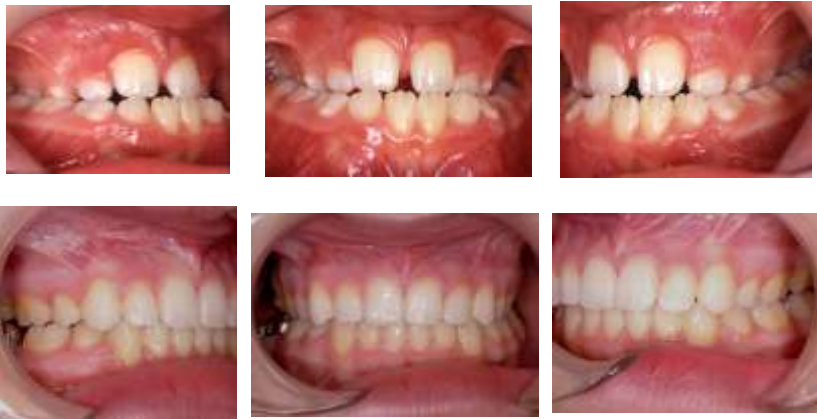

Wits -6 mm



wits -12 mm

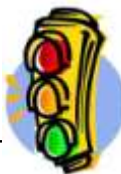**Comparison—Pre and post treatment
Surgery required—Lefort lengthen AP and V**

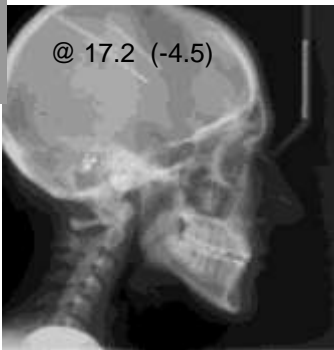
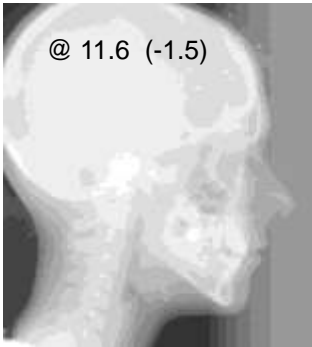
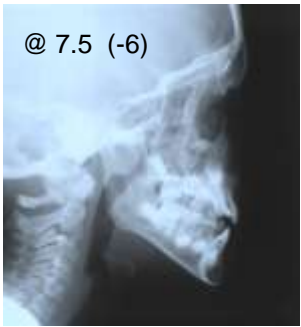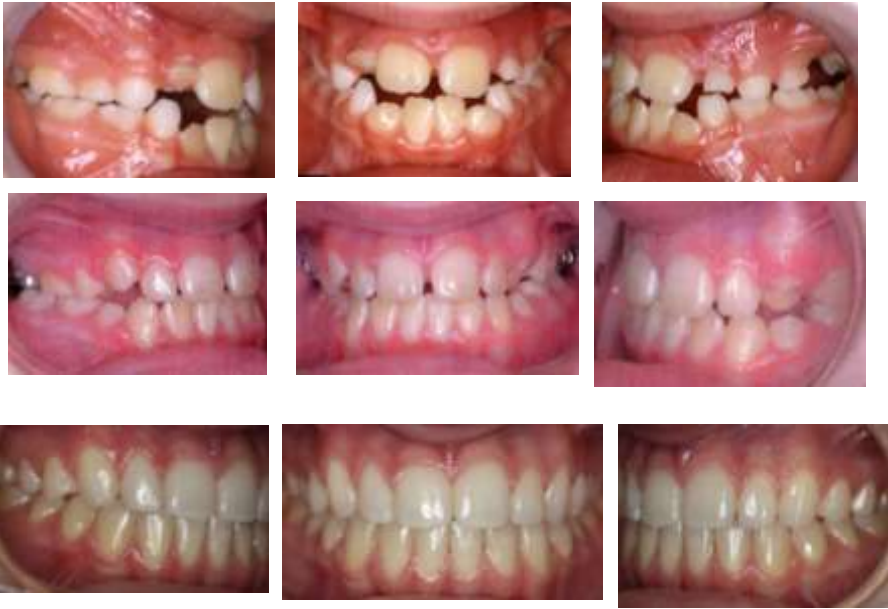Case #3

Checklist (at Phase II Conf.) for Class III-ing Pts.

Hypothesis	
<i>All early Class III's require Therapeutic Dx</i>	
Patient's Name: _____ E.K. _____ Age _____ Skel. Age _____	
Male	<u>Female</u>
✓ Family history	Yes No _____
✓ Initial diagnosis (mnd excess)	Yes No (%Max vs. Mand) <u>Mild</u>
✓ Response to Ph I	Good Poor _____
✓ Diagnosis @ Ph II (Wits)	Mild Mod. Severe
✓ Facial balance	Mild Mod. Severe
✓ Skeletal age @ Ph II	Favorable Unfavorable _____
✓ Growth pattern	Favorable Unfavorable (asym/open)
✓ Ging Health/Root length	Favorable Unfavorable _____
✓ Capacity to Camouflage	Favorable Unfavorable _____
✓ Compliance	Favorable Unfavorable _____
✓ Growth hormone	Yes No
Phase II Decision Time: Non-surg; Thera dx; Wait & plan s	





Orthodontic Removable Traction Appliance (ORTA)

Indications and Utilization

CLASS III MALOCCLUSION

Anterior crossbite - Disarticulate

- Mixed dentition or adult dentition with anterior crossbite and some amount of functional shift benefit from a lower Class III anchor plate; if posterior bite plane is needed, it can be added to avoid incisor trauma while crossbite correction occurs

Class III - Maxillary Deficiency

- Lower Class III anchor plate is frequently useful with patients that are also undergoing RPE, partial braces, and orthopedic traction to enhance maxillary horizontal growth. The RTA can be worn 24 hours per day (high compliance), the face mask 10-12 hours per day.

Functional Shift - Class III

- Same as above; "anterior crossbite to disarticulate"

Surgically Assisted R.P.E. - Class III

- Adult cases with surgically assisted R.E. and mild maxillary deficiency can be treated with lower Class III anchor plate to apply traction to maxilla during healing of osteotomy. Forward positioning of maxilla has been documented.

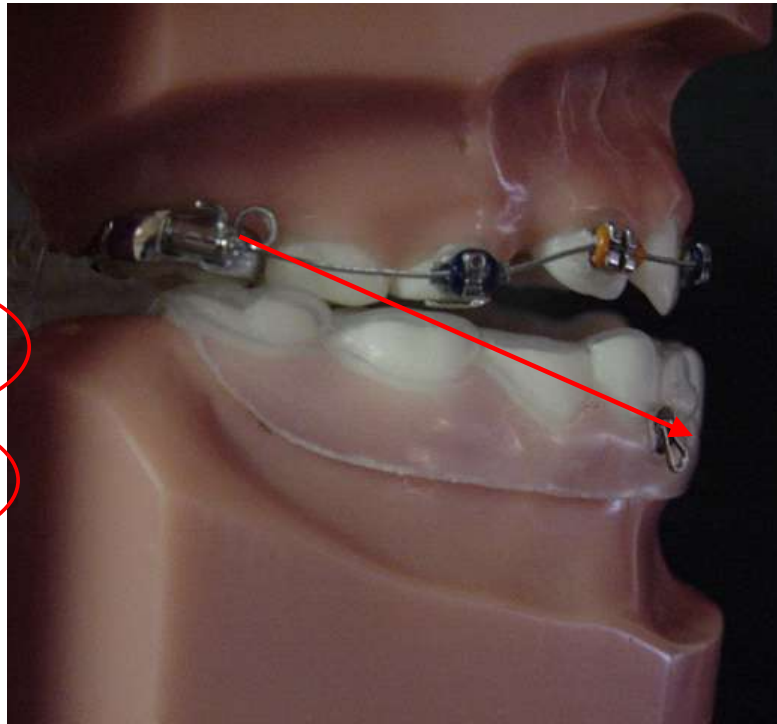
Orthodontic re-treatment of Class III tendency

- Several males and an occasional female will grow out of orthodontic correction. Upper Class III RTA helps in mild cases. Lower braces are placed, discing to the [4 5 3] area and Class III traction to correct the Class III tendency of the lower arch.

ORTA®

Orthodontic *Removable Traction Appliance*

- ✓ Intraoral
- ✓ Inexpensive
- ✓ High compliance
- ✓ Disarticulation
- ✓ Easily adjusted



CLINICAL STEPS ORTA—Orthodontic removable traction appliance

Determine traction requirements (II, III, crossbite, or vertical)

- Adhesive “retentive ridges” should be placed on an area where optimal elastic traction is to be applied.

Prepare teeth for adhesive “retentive ridges”

- Typical acid etch technique.

Add adhesive “retentive ridges” to stabilize appliance during traction - 75% M-D; 2-3 mm height

- Better to “over do” slightly; the “retentive ridges” can be trimmed easier than adding more adhesive.

Alginate impression

- Typical steps

LABORATORY STEPS ORTA—Orthodontic removable traction appliance

Stone Model

1. Trim for vacuum form;
2. Relieve undercuts (except “retentive ridges”)
3. Check for retention of “retentive ridges”;
NOTE: use smaller retentive ridges with less retention when using biocryl for RTA
4. Make sure that “retentive ridges” are large enough on the tooth for adequate retention;
Then, when the model is poured up, lightly scrape plaster around the area of the “retentive ridges” so they are well defined;

Durasoft Material (*Great Lakes Orthodontic Products*)

1. Catalog number = 030-001 (box of 10)
2. Price @ \$4.99 per sheet

Vacuum Form to model

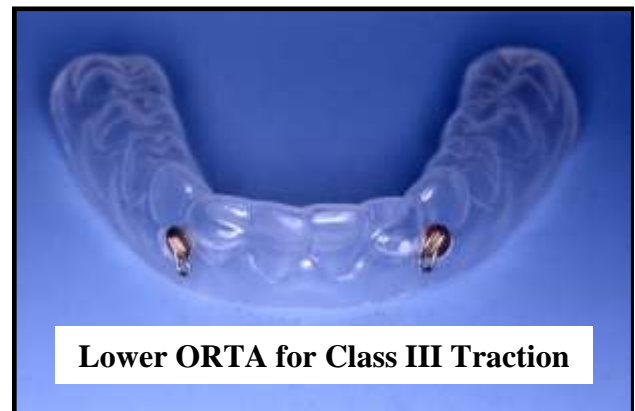1. Trim with diamond disc
2. Smooth edges with diamond bur
3. Be sure to leave > 2 mm under retentive ridges to aid in retention

Add Caplin Hooks (GAC) for elastic traction.

1. Heat Kaplan hook (*GAC International*) with torch and place in the area of desired traction.
2. After inserting the hook into the plastic (essix, biocryl or durasoft) material, check the underside to make sure that the hook is not showing through the plastic
3. Pull hook to be sure it's attached to material securely; it should not be able to be detached from elastic pull.

Essix “C” (“Invisacryl”) -*Great Lakes Orthodontic*

1. Catalog number =021-056 [box of 100]
2. Price @ \$0.59 per sheet



Lower ORTA for Class III Traction

References for Early Class III Treatment

I. Diagnosis of the Class III Skeletal Problem

1. **Proffit WR, Fields HW, Moray LJ.** *Prevalence of malocclusion and orthodontic treatment need in the United States: Estimates from the N-HANES III survey.* Int J Adult Orthod Orthogn Surg 1998; 13:97-106.
2. **Keski-Nisula K, Lehto R, Lusa V, Keski-Nisula L, Varrela J.** *Occurrence of malocclusion and need for orthodontic treatment in early mixed dentition.* Am J Orthod Dentofacial Orthop 2003; vol. 124 number 6.
3. **Nakasirna A, Ichinose M.** *Role of parental variables in predicting facial growth after treatment of anterior crossbite.* Am J Orthod Dentofacial Orthop 1986 Dec. 492-500.
4. **Proffit WR, Ackermann JL.** *A systematic approach to orthodontic diagnosis and treatment planning.* In: Graber TM, Swain BF, editors. Current orthodontic concepts and techniques. 3rd ed. Saint Louis: CV Mosby; 1985.
5. **McNamara JA.** *A method of cephalometric evaluation.* Am J Orthod. 1984 Dec; 86(6):449-69.
6. **Guyer EC, Ellis EE, McNamara JA, Behrents RG.** *Components of Class III Malocclusion in Juveniles and Adolescents.* Angle Orthod, January, 1986: 7-30.
7. **Casko JS, Shepherd WB.** *Dental and Skeletal Variation Within The Range of Normal.* The Angle Orthodontist 1984; 54: 5-17.

II. Therapeutic Approaches

8. **Sakamoto T, Iwase I, Uka A, Nakamura S.** *A roentgenocephalometric study of skeletal changes during and after chin cup treatment.* Am J Orthod 1984; 85:341-50.
9. **Sugawara J, Asano T, Endo N, Mitani H.** *Long-term effects of chin cup therapy on skeletal profile in mandibular prognathism.* Am J Orthod Dentofacial Orthop 1990; 98: 127-33.
10. **McNamara W.** *Functional regulator (FR-3) of Frankel.* Am J Orthod Dentofacial Orthop Nov. 1995.
11. **Westwood PV, McNamara JA, Baccetti T, Franchi L, Sarver DM.** *Long-term effects of Class III treatment with rapid maxillary expansion and facemask therapy followed by fixed appliances.* Am J Orthod Dentofacial Orthop 2003; 123:306-20.
12. **McNamara JA.** *An Orthopedic Approach to the Treatment of Class III Malocclusion in Young Patients.* JOC Sept. 1987; 21:598-608.
13. **Ngan P, Wei SH, Hagg U, et al.** *Effect of protraction headgear on Class III malocclusion.* Quintessence International 1992; 23:197-202.
14. **Hickham JH.** *Maxillary Protraction Therapy: Diagnosis and treatment.* JOC 1991 Feb; 102-113.
15. **Kokich VG, Shapiro PA, et al.** *Ankylosed teeth as abutments for maxillary protraction: a case report.* Am J Orthod Dentofacial Orthop 1985 Oct. 303-307.
16. **Wendell PD, Nanda R, Sakamoto T, Nakamura S.** *The Effects of Chin Cup Therapy on the Mandible: A Longitudinal Study.* Am J Orthod. 1985 Apr; 87 (4): 265-74.
17. **Sakamoto T, Iwase I, Uka A, Nakamura S.** *A Roentgenocephalometric Study of Skeletal Changes During and After Chin Cup Treatment.* Am J Orthod. 1984 Apr; 85(4): 341-50.

18. **Elstein S.** *On the Origins and Development of Evidence-based Medicine and Medical Decision Making.* Inflammation Research. 2004 August; 184-189.

III. Therapeutic Diagnosis and Treatment Responses

19. **Hagg U, Tse Agnes, Bendeus M, Rabie ABM.** *Long-term follow-up of early treatment with reverse headgear.* European Journal of Orthodontics 2003; 25:95-102.
20. **Kapust AJ, Sinclair PM, Turley PK.** *Cephalometric effects of face mask/expansion therapy in Class III children: a comparison of three age groups.* Am J Orthod Dentofacial Orthop 1998 Feb; 113(2):204-12.
21. **Dermaut LR, Aelbers CMF.** *Orthopedics in Orthodontics: Fiction or reality. A review of the literature - Part II.* Am J Orthod Dentofacial Orthop 1996; 110: 667-71.
22. **Yuksel S, Ucem TT, Keykubat A.** *Early and Late Facemask Therapy.* Eur J Orthod. 2001 Oct; 23(5): 559-68.
23. **Basdra EK, Stellzig A, Komposch G.** *Dentofacial Changes in Patients With Class III Malocclusions Treated by a Combination of Activator and Chin-cup Appliances.* Aust Orthod J. 1997 Mar; 14(4): 225-8.
24. **Suda N, Ishii-Suzuki M, Hirose K, Hiyama S, Suzuki S, Kuroda T.** *Effective Treatment Plan for Maxillary Protraction: Is the Bone Age Useful to Determine the Treatment Plan?* Am J Orthod Dentofacial Orthop. 2000 Jul; 118(1): 55-62.
25. **Merwin D, Ngan P, Hagg U, Yiu C, Wei SH.** *Timing For Effective Application of Anteriorly Directed Orthopedic Force to the Maxilla.* Am J Orthod Dentofacial Orthop. 1997 Sept; 112(3): 292-9.
26. **Zentner A, Doll GM, Matthias Peylo S.** *Morphological Parameters as Predictors of Successful Correction of Class III Malocclusion.* European Journal of Orthodontics 23 (2001) 383-392.

IV. Treatment Outcomes—Long-term Follow-up

27. **Musich DR.** *Report of 100 orthodontic retreatment cases: Learning from "failures."* Unpublished report presented to Eastern Component Angle Society, 1988.
28. **Stellzig-Eisenhauer A, Lux CJ, Schuster G.** *Treatment decision in adult patients with Class III malocclusion: Orthodontic therapy or orthognathic surgery?* Am J Orthod Dentofacial Orthop 2002; 122:27-38.
29. **Hagg U, Tse A, Bendeus M, Rabie AB.** *Long-term Follow-up of Early Treatment with Reverse Headgear.* Eur J Orthod. 2003 Feb; 25(1): 95-102.
30. **Deguchi T, Kitsugi A.** *Stability of Changes Associated With Chin Cup Treatment.* Angle Orthod. 1996; 66(2): 139-45.
31. **Takada K, Petdachai S, Sakuda M.** *Changes in Dentofacial Morphology in Skeletal Class III Children Treated by a Modified Maxillary Protraction Headgear and a Chin Cup: A Longitudinal Cephalometric Appraisal.* Eur J Orthod 1993 Jun; 15(3): 211-21.
32. **Gavakos K, Witt E.** *The Functional Status of Orthodontically Treated Prognathic Patients.* Eur J Orthod 1991 Apr; 13(2): 124-8.